

Healing of Diabetic Foot Ulcers and Pressure Ulcers With Human Skin Equivalent

A New Paradigm in Wound Healing

Harold Brem, MD; Jeroen Balledux, MD; Tamir Bloom, BA;
Morris D. Kerstein, MD; Larry Hollier, MD

Hypothesis: In patients with diabetic foot and pressure ulcers, early intervention with biological therapy will either halt progression or result in rapid healing of these chronic wounds.

Design: In a prospective nonrandomized case series, 23 consecutive patients were treated with human skin equivalent (HSE) after excisional debridement of their wounds.

Setting: A single university teaching hospital and tertiary care center.

Patients and Methods: Twenty-three consecutive patients with a total of 41 wounds (1.0-7.5 cm in diameter) were treated with placement of HSE after sharp excisional debridement. All patients with pressure ulcers received alternating air therapy with zero-pressure alternating air mattresses.

Main Outcome Measure: Time to 100% healing, as defined by full epithelialization of the wound and by no drainage from the site.

Results: Seven of 10 patients with diabetic foot ulcers had complete healing of all wounds. In these patients 17

of 20 wounds healed in an average of 42 days. Seven of 13 patients with pressure ulcers had complete healing of all wounds. In patients with pressure ulcers, 13 of 21 wounds healed in an average of 29 days. All wounds that did not heal in this series occurred in patients who had an additional stage IV ulcer or a wound with exposed bone. Twenty-nine of 30 wounds that healed did so after a single application of the HSE.

Conclusions: In diabetic ulcers and pressure ulcers of various durations, the application of HSE with the surgical principles used in a traditional skin graft is successful in producing healing. The high success rate with complete closure in these various types of wounds suggests that HSE may function as a reservoir of growth factors that also stimulate wound contraction and epithelialization. If a wound has not fully healed after 6 weeks, a second application of HSE should be used. If the wound is not healing, an occult infection is the likely cause. All nonischemic diabetic foot and pressure ulcers that are identified and treated early with aggressive therapy (including antibiotics, off-loading of pressure, and biological therapy) will not progress.

Arch Surg. 2000;135:627-634

THE MORBIDITY and mortality from a venous stasis ulcer, diabetic foot ulcer, or pressure ulcer (sacral, gluteal, or trochanteric) presents a considerable health care problem. We calculated from multiple sources that in the United States, the total prevalence of all 3 of these types of ulcers is between 3 and 6 million.¹⁻³ These physiologically impaired and slow-to-heal wounds place a great burden on the health system, with costs of billions of dollars. The true costs of such chronic wounds, however, cannot be estimated solely by their enormous health care expenditures. The pain and suffering incurred by a patient who enters the hospital for a medical disease and leaves with a sacral ulcer goes far beyond the costs of that wound.

Among 16 million patients with diabetes (diagnosed and undiagnosed) in the United States, there are an estimated 1200 amputations performed each week,⁴ 84% of which are preceded by a foot ulcer.⁵ Limb amputation in patients with diabetes is associated with an increased risk for further amputation, which has a 5-year mortality rate of 39% to 68%.⁶ The direct costs of these lower-extremity amputations in patients with diabetes range from \$20 000 to \$60 000.⁷ When the cost of failed vascular reconstruction and rehabilitation—as well as lost productivity within society—are accounted for, these expenses exceed financial analysis. The grave consequences of diabetic ulcers to patients make it necessary to determine the best combination of therapies to prevent progression.

From the Department of Surgery, The Mount Sinai Medical Center, New York, NY.

This study was supported in part by a research grant from Pegasus Airwave Inc, Boca Raton, Fla (Dr Brem).

PATIENTS, MATERIALS, AND METHODS

In this report we detail all of the consecutive pressure and diabetic foot ulcers that were treated with Apligraf. The patients were treated over 9 months with a follow-up period ranging from 2 to 10 months.

All wounds were prepared in the following standard fashion: the wound base was excised and wound edges were extended by approximately 1 mm. Brisk capillary bleeding from all wound surfaces was attained. The goal of surgical debridement was to remove all necrotic and grossly infected material, as well as all scar tissue.

Twenty-three consecutive patients were treated with Apligraf (10 patients had diabetic ulcers; 13, pressure ulcers). The treatment period extended for 10 months, and the follow-up period ranged from 2 to 9 months. All chronic ulcers were treated only after they showed a minimum of drainage and the presence of well-vascularized granulation tissue. There were 3 wounds that extended to bone (2 diabetic and 1 pressure ulcer). The wounds ranged in diameter from 1 cm to 7.5 cm. Apligraf was placed on the wound after complete hemostasis was attained. Apligraf was applied as a skin graft with interrupted 5-0 absorbable sutures, leaving a distance of approximately 1 mm between the new skin edge of the wound and the edge of Apligraf. Afterward, Adaptic (Johnson & Johnson, New Brunswick, NJ) was placed over the graft, followed by xeroform wrapped around sterile cotton, followed by Tegaderm (3M Health Care, Memphis, Tenn).

All patients who had cellulitis associated with diabetic foot ulcers were treated with intravenous antibiotics. In all patients, culture specimens from deep tissue were obtained after the superficial tissue has been excised; those

with findings positive for bacterial growth were treated with antibiotics. We educated all patients on how best to relieve pressure. Although crutches were prescribed, patients were often noncompliant with this aspect of therapy.

Pressure ulcers were staged in the following manner and represent the National Pressure Advisory Panel guidelines, published by the Agency for Health Care Policy and Research, Rockville, Md³⁶:

- Stage I: Nonblanchable erythema of intact skin; the heralding lesion of skin ulceration. In individuals with darker skin, discoloration of the skin, warmth, edema, induration, or hardness may also be indicators.
- Stage II: Partial-thickness skin loss involving epidermis or dermis or both. The ulcer is superficial and presents clinically as an abrasion, blister, or shallow crater.
- Stage III: Full-thickness skin loss involving damage or necrosis of subcutaneous tissue, which may extend down to but not through underlying fascia. The ulcer presents clinically as a deep crater with or without undermining of adjacent tissue.
- Stage IV: Full-thickness skin loss with extensive destruction, tissue necrosis, or damage to muscle, bone, or supporting structures (such as tendon and joint capsule). Undermining and sinus tracts also may be associated with stage IV pressure ulcers.

All patients with pressure ulcers received alternating air therapy with the Renaissance zero-pressure alternating air mattress (Pegasus Airwave Inc, Boca Raton, Fla). Surgical debridement was performed on all patients in a setting in which adequate hemostasis could be obtained. Although most patients were treated in the operating room, debridements were also performed on both outpatients and inpatients. The 3 patients who were lost to follow-up evaluation were considered to have had nonhealing wounds.

Pressure ulcers also cause pain, lost productivity, and huge expenditures.⁸ Pressure ulcers are common in the elderly population, in patients who are bedridden, in patients with spinal cord injury, and after major orthopedic reconstruction. The prevalence of pressure ulcers (stage II and greater) is estimated to be up to 17% among hospitalized patients,^{9,10} at least 12% among patients in nursing homes, and 20% to 30%^{11,12} among patients with spinal cord injury and in rehabilitation units. Furthermore, pressure ulcers are associated with an increased mortality, especially if healing does not occur.¹³⁻¹⁵ The healing rate for stage II ulcers that extend only into the dermis has been as low as 26% at 6 months.¹⁶ In practical terms, it is not uncommon for patients to be discharged with large unhealed ulcers. With a burgeoning aging population, it is imperative to develop new treatments for these ulcers. Prevention is the ideal solution, but we hypothesize that early intervention halts progression and its ensuing morbidity and mortality.

Healing of acute wounds, such as surgical incisions, occurs sequentially, in a timely fashion, and without definitive intervention. Platelets enter the wound and secrete growth factors that subsequently recruit macrophages into the wound. These macrophages also release growth factors¹⁷ that cause endothelial cells to migrate

and proliferate in the wound, thereby stimulating angiogenesis and the fibroblasts to synthesize collagen.¹⁸

The orderly and timely reparative process characteristic of acute wounds results in a sustained restoration of anatomic and functional integrity.¹⁹ A chronic wound is characterized by failure to heal in a timely and orderly process, compromising anatomic and functional integrity.^{19,20} Diabetic foot ulcers and pressure ulcers are all chronic wounds, and intervention is always necessary to prevent their further progression.

Biological therapy and the use of human skin equivalent (HSE) are ideal treatments for chronic ulcers because they add additional cells and growth factors to a deficient wound-healing environment. The risk of wound infection is decreased by accelerating healing time. New drugs have been approved by the Food and Drug Administration, Washington, DC, to accelerate the closure of nonhealing wounds (eg, platelet-derived growth factor-BB, also known as Regranex²¹⁻²³ [Ortho-McNeil, Raritan, NJ] and the HSE Apligraf [also known as Graftskin; synthesized by Organogenesis Inc, Canton, Mass, and distributed by Novartis Pharmaceuticals Corp, East Hanover, NJ]²⁴⁻³²), a development that has begun (and no doubt will continue) to transform the field. Wound healing requires practical outcome-related data, which is a standard for measuring the effectiveness of any treat-

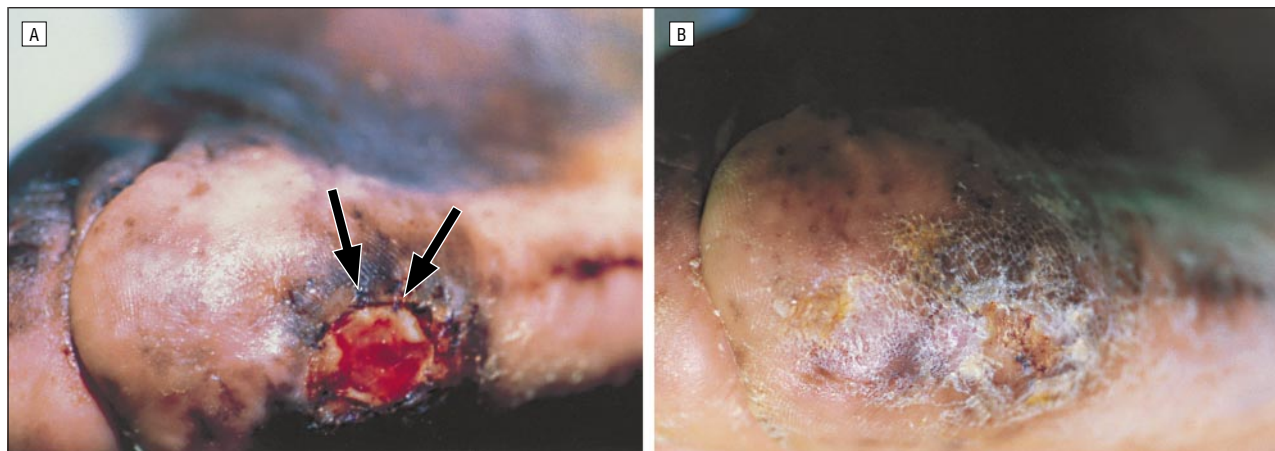


Figure 1. A, Diabetic foot ulcer in the lateral metatarsal area present for 14 months. Patient had other leg amputated secondary to wound complication. Photograph taken in office 1 week after human skin equivalent was placed. Arrows point to where sutures were placed and demonstrate considerable amount of contraction in only 1 week. B, One month after an application of human skin equivalent, the diabetic foot ulcer was healed completely.

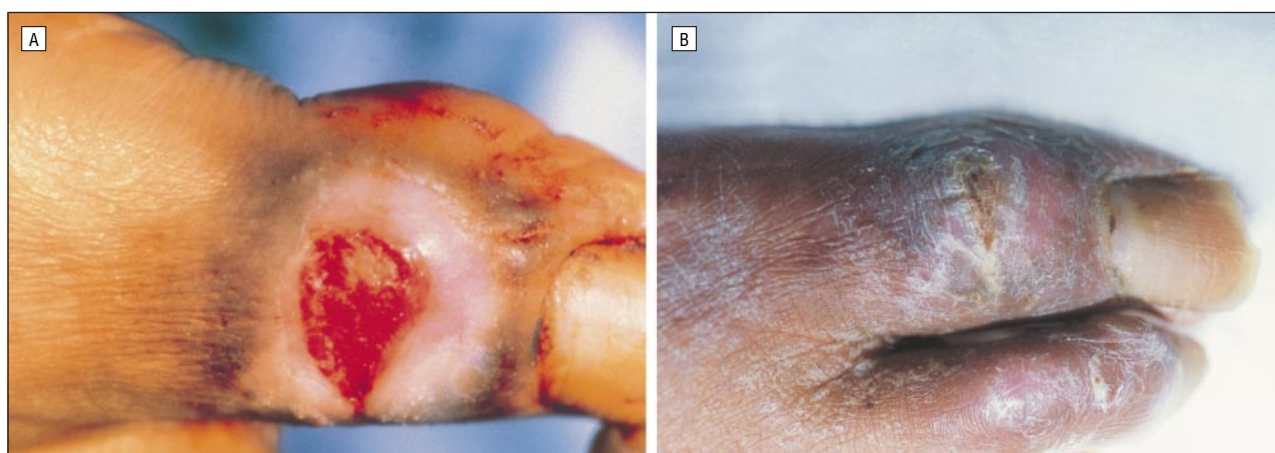


Figure 2. A, Diabetic foot ulcer in the unusual location of the dorsal surface of the first toe. After a single application of Apligraf (synthesized by Organogenesis Inc, Canton, Mass, and distributed by Novartis Pharmaceuticals Corp, East Hanover, NJ) applied in the standard fashion, the wound was healed completely and epithelialized. B, Picture taken 8 weeks after single application.

ment. Therefore, we describe our initial results using HSE for patients with diabetic foot and pressure ulcers.

The HSE Apligraf has been approved by the Food and Drug Administration to accelerate the closure of non-healing wounds. Apligraf is a bilayered living-skin construct containing an outer layer of live allogeneic human keratinocytes and a second layer of live allogeneic fibroblasts on type 1 collagen dispersed in a dermal layer matrix.^{27,33-35} Both cell layers are grown from infant foreskin. Apligraf looks and feels like human skin; however, its biological activity is distinct from that of an autologous skin graft in that it is a potent stimulator of wound healing.

In a multicenter clinical trial for patients (N=120) who had venous ulcers for longer than 1 year, Apligraf plus compression therapy proved almost 3 times more effective in 100% closure of wounds, as measured at 24 weeks (46% vs 19% of control patients who did not receive Apligraf) ($P=.002$).³² On the basis of this published evidence, we therefore began treating nonhealing venous stasis ulcers present for longer than 1 year with Apligraf and had similar results. Therefore, we hypothesized that a single application of Apligraf applied early

in the course of ulcer formation, specifically in the population of patients with diabetes and in those with superficial pressure ulcers, could prevent the progression of these wounds and possibly accelerate their closure.

RESULTS

Ten patients with diabetes were treated. Of these, 7 had all wounds heal (**Figure 1** and **Figure 2**); 86% of diabetic wounds healed in total (**Table 1**). Two patients needed between 3 and 6 months for their wounds to heal. One of these patient's wounds was a 5-cm-diameter heel ulcer, which developed after a coronary artery bypass graft; the other patient's wound was the result of a burn. We subsequently treated a patient with diabetes who had ascending cellulitis and who received intravenous antibiotics. He then received Apligraf as an outpatient 6 weeks after the first application of HSE, which resulted in 100% closure of his wound.

Wound healing in 3 patients with diabetes failed: 2 wounds were on toes in which there was necrosis of the distal phalanx. We anticipated a toe amputation in both patients, which occurred within 30 days of the initial debridement. Apligraf was placed on the bones of these pa-

Table 1. Clinical Characteristics of Patients With Diabetes*

Patient No./ Sex/Age, y	Race	No. of Ulcers	Size of Largest		Location of Ulcer	Etiology	Other Factors	No. of Apligraf Applications	Healed
			No. of Ulcers	Ulcer, cm					
1/M/39	African American	2, 1 Healed	1.0 × 1.2	4.3 × 3.0	Right foot	NIDDM	Infected, failed muscle flap Wound 50% healed	1	Y N
2/F/69	Hispanic	6	5.8 × 2.0		Toes, metatarsals	NIDDM	Cellulitis	1	Y
3/M/64	White	1	5.2 × 3.0		Left heel	NIDDM	MRSA, status post CABG	1	Y
4/F/40	African American	1	3.9 × 1.9		Right heel	IDDM	Burn injury	1	Y
5/M/67	White	1	2.1 × 1.9		Left plantar	IDDM	ABI, 0.77; presented with ascending cellulitis	2	Y
6/M/75	African American	2	2.0 × 1.0		First toe, dorsum of foot	NIDDM	ABI, 0.76	1	Y
7/F/51	Hispanic	4	4.6 × 0.9		Toes, metatarsals	NIDDM	Lupus	1	Y
8/M/37	White	1	1.0 × 0.8		Right foot	IDDM	Burn injury	1	Y
9/M/45	White	1	...		Left first toe	NIDDM	Gangrene	1	N
10/F/87	African American	1	...		Right first toe	NIDDM	Gangrene	1	N

*M indicates male; NIDDM, non-insulin-dependent diabetes mellitus; Y, yes; N, no; F, female; MRSA, methicillin-resistant *Staphylococcus aureus*; CABG, coronary artery bypass grafting; IDDM, insulin-dependent diabetes mellitus; ABI, arterial brachial index; and ellipses, not available.

Table 2. Clinical Characteristics of Patients With Pressure Ulcers*

Patient No./ Sex/Age, y	Race	No. of Ulcers	Size of Largest		Location of Ulcer	Other Factors	No. of Apligraf Applications	Healed
			No. of Ulcers	Ulcer, cm				
1/M/87	White	1	1.4 × 1.7		Sacrum	Parkinson disease	1	Y
2/F/65	White	1	1.4 × 0.8		Sacrum	Diabetes	1	Y
3/F/66	Hispanic	3	4.6 × 4.7		Buttocks	CVA	1	Y
4/F/82	White	1	2.8, depth		Right hip	CVA	1	Y
5/F/91	White	1	1.0 × 0.8		Sacrum	Status post ECT	1	Y
6/M/72	White	1	3.0 × 2.0		Sacrum	Quadriplegia	1	Y
7/M/45	White	3	7.5 × 3.0		Buttocks/sacrum	CABG, NIDDM	1	Y
8/F/30	African American	3, 2 Healed	1.0 × 2.0		Sacrum	Anoxic brain injury	1	Y
			2.0 × 3.0		Buttocks			Y
			4.0 × 2.0		Sacrum			N
9/M/32	African American	1	3.7 × 2.0		Right hip	Concurrent left hip abscess, necrotic bone, MRSA	1	N
			2.1, depth					
10/M/51	White	1	3.0 × 2.0		Sacrum	Lost to follow-up	1	N
11/M/83	White	1	4.0 × 4.5		Buttock	Concurrent stage IV ulcer, necrotic bone, <i>Pseudomonas</i>	1	N
12/M/30	Hispanic	3	4.8 × 4.7		Sacrum/buttocks	<i>Pseudomonas aeruginosa</i>	3	N
13/F/72	White	1	2.0 × 1.0		Sacrum	Anoxic brain injury	1	N

*M indicates male; Y, yes; F, female; CVA, cerebral vascular accident; ECT, electroconvulsive therapy; CABG, coronary artery bypass grafting; NIDDM, non-insulin-dependent diabetes mellitus; N, no; and MRSA, methicillin-resistant *Staphylococcus aureus*.

tients, and though it provided an effective biological dressing, we considered these instances to be failures of treatment with Apligraf because we included in our results every wound on which Apligraf was placed, regardless of intent to heal. The only other diabetic wound that did not heal in this series was in a patient in renal failure who already had a contralateral below-the-knee amputation. He had a purulent draining wound on a failed necrotic muscle flap (5-cm diameter) in his right distal foot and a separate ulcer along the lateral first metatarsal (Figure 1). The wound on the necrotic muscle flap healed 50% of its area with smooth new skin within 6 weeks of a single Apligraf application; however, the remainder of the wound did not heal until additional tissue of the muscle flap was debrided. Although this wound subsequently began to contract to a depth of 3 cm after it was debrided, it was nevertheless considered to be nonhealing.

Of the patients with pressure ulcers, 7 of 13 had all wounds heal; 13 of 21 wounds healed in an average of

29 days (Table 2, Figure 3, and Figure 4). All wounds that healed required only a single application of Apligraf. Five of 6 patients whose wounds did not heal with Apligraf had the concurrent presence of a stage IV ulcer. The sixth patient's wound was a stage III ulcer, the size of which had decreased by 50%; however, the patient died 2 months after the Apligraf application as a consequence of an anoxic brain injury (Table 2).

Many of these same patients had wounds less than 1 cm in diameter, which were also treated with Apligraf. All of these wounds healed, but because the wounds were initially so small, they were not included in this report.

COMMENT

In this article, we describe a safe and considerable healing response using Apligraf treatment for diabetic foot ulcers. In 18 consecutive diabetic foot wounds, notable

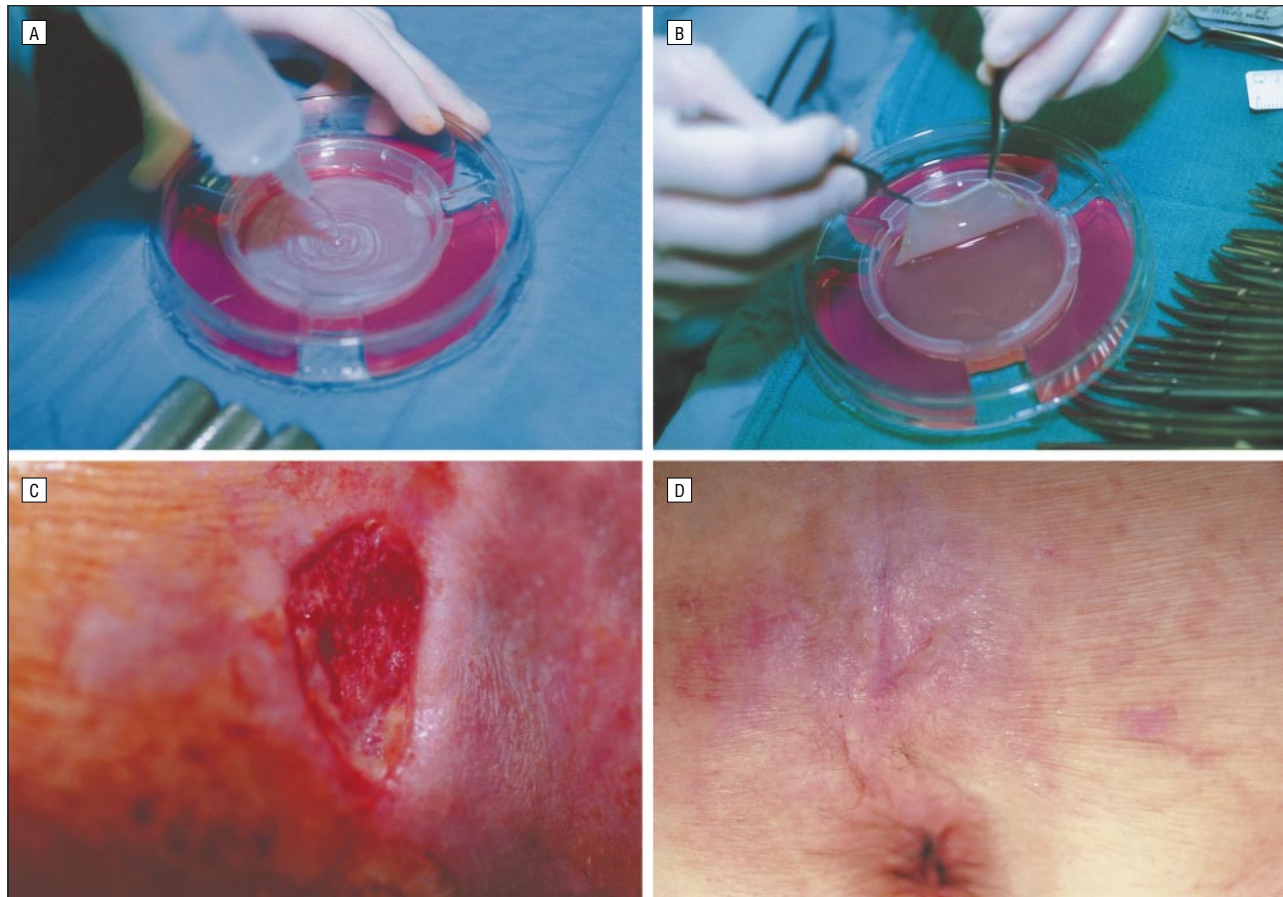


Figure 3. A, Saline being applied in Petri dish (keratinocyte layer) such that Apligraf can be easily removed from its culture medium. B, Apligraf being lifted with 2 smooth forceps (fibroblast side showing). C, Quadriplegic who had nonhealing sacral ulcer. In this photograph, the wound was debrided down to subcutaneous tissue. D, This wound healed 3 weeks after application of the skin graft, 1 week before photograph was taken.

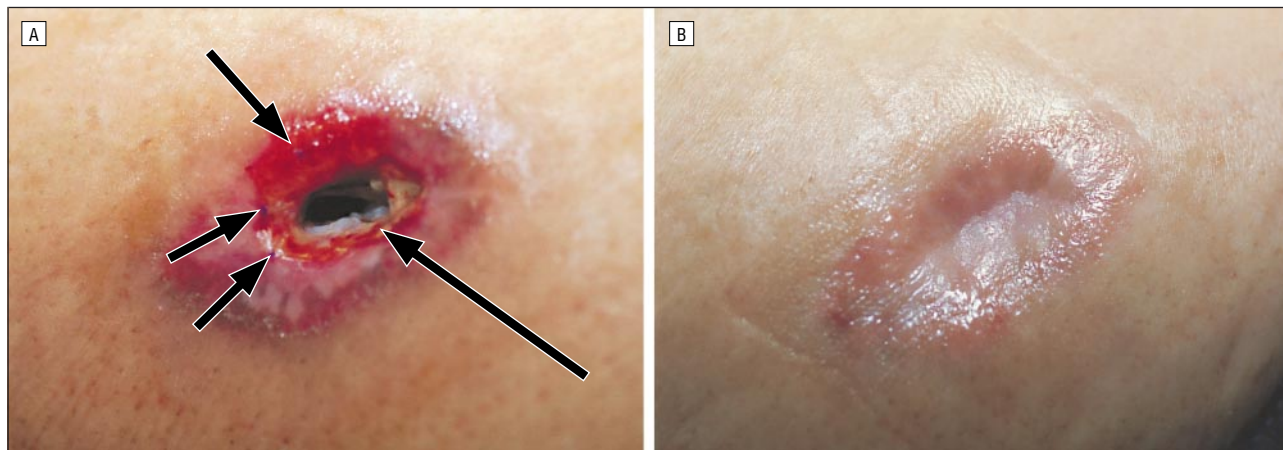


Figure 4. A, Three days after Apligraf was sutured into pressure ulcer with depth in right trochanteric area of 2.8 cm. Short arrows point to sutures. Long arrow points to human skin equivalent. B, Seven weeks later, it filled in with granulation tissue and had fully epithelialized, suggesting effectiveness of Apligraf in forming granulation tissue and aiding in epithelialization.

healing resulted after a single application of Apligraf. Furthermore, in patients whose surface pressure ulcers were treated with Apligraf and with alternating air therapy with zero-pressure alternating air mattresses (and who did not have a simultaneous stage IV ulcer), all wounds healed. None of 41 wounds in patients treated with Apligraf progressed under this wound-healing paradigm. Therefore, this type of biological

therapy should be considered in all new diabetic foot ulcers or pressure ulcers to prevent progression of these highly morbid disease processes.

The advantage of early intervention in wounds has been clearly established (eg, in patients with burns). The burn wound is a site for colonization by endogenous and exogenous organisms. Effective topical antimicrobial chemotherapy and early burn wound excision have consid-

erably reduced the overall occurrence of invasive burn wound infections and have subsequently increased survival rates.³⁷ The lessons learned from burn wounds can be translated to chronic wounds. In physiologically impaired wounds such as diabetic foot ulcers, higher debridement rates correlate directly with higher healing rates.³⁸ In our series, patients required no more than 2 debridements prior to Apligraf application. The decreased amount of debridement in our series can be explained by the extensive sharp debridement that we performed on the initial debridements as well as the fact that patients in this study did not have considerable depth to their wounds on initial presentation. In our experience, debriding any wound to the level at which scar and infection are no longer present (even if down to the bone) has proved to be safe and therapeutic. Similarly, viable tissue should not be excised. In particular, the wound margins should not be extended more than 1 mm or 2 mm.

Alternating air therapy has been demonstrated to considerably increase blood flow³⁹ in the sacral area. We have observed that the use of a Renaissance zero-pressure alternating air mattress (Pegasus Airwave Inc) for more than 100 consecutive patients prevented progression of a decubitus ulcer. We recommend this type of therapeutic bed treatment for patients who receive skin grafts. Future studies are necessary to ascertain the specific therapeutic effects of this mattress and to determine the angiogenic response to Apligraf.

Our data suggest that osteomyelitis prevents Apligraf from being effective in an area in which the wound is adjacent to the area of osteomyelitis. The wounds of 9 patients in our study did not all heal; some of these patients had osteomyelitis and others had concurrent infection. We hypothesize that the presence of an ulcer with active infection considerably impedes the healing process in other ulcers that are nearby.

One possible limitation of our study in design is that it was a nonrandomized study with no placebo group. However, it now has been established in separate prospective, randomized, placebo-controlled studies that Apligraf accelerates closure of 2 types of chronic wounds (eg, venous^{28,32} and diabetic⁴⁰). Investigators at the Deaconess-Joslin Foot Center, Boston, Mass, report that HSE significantly accelerates the closure of nonhealing diabetic wounds; specifically, they found that nonhealing diabetic foot ulcers close in an average of 39 days compared with 91 days for the control group.⁴⁰ We observed that if a patient responds to HSE, the wound will begin to contract within the first 3 weeks after Apligraf application. We chose 6 weeks for the second application of Apligraf based on our clinical experience, which suggests the maximal effect of the first graft occurs at this time. In all patients whose wounds healed, only 1 or 2 applications of Apligraf were necessary (Table 1 and Table 2). This is significantly less graft material than that used in the clinical trials (eg, venous^{28,32} and diabetic⁴⁰) to demonstrate Apligraf's clinical efficacy. This may provide further cost savings to the patient.

It is well established that patients with diabetes are at high risk for developing foot ulcers. Equally important is the fact that once a patient with diabetes devel-

ops an open wound, he or she is further hampered by both impairments in wound healing and an increased susceptibility for wound infection.⁴¹ These factors help explain why nearly half (46%) of 162 500 annual hospitalizations for foot ulcers in the United States occur in patients with diabetes (16 million diagnosed and undiagnosed cases in the United States).⁴ Foot ulcers precede 85% of all nontraumatic lower limb amputations in the United States, half of which are performed in patients with diabetes.⁴² In addition, limb amputation in patients with diabetes is associated with an increased risk for further amputation, which has a 5-year mortality rate of 39% to 68%.⁶ The direct costs of these lower extremity amputations in patients with diabetes range from \$20 000 to \$60 000.⁷ A cost of a single application of Apligraf is approximately \$1000. Further studies will be required to determine the direct cost benefit.

Certain types of wounds may require more than a single type of biological therapy. In the future, HSE may be used in synergy with some other drugs currently available for patients in whom wounds do not heal. In the United States, some of the other available interventions include recombinant human platelet-derived growth factor,^{21-23,43} which has been shown to significantly increase granulation tissue, contraction, and time to healing in diabetic foot ulcers. In addition, granulocyte macrophage colony-stimulating factor,⁴⁴⁻⁵⁰ which recruits macrophages into the wound and is thought to release multiple other growth factors as well, has also been shown to be effective in the acceleration of healing of diabetic foot, pressure, and venous stasis ulcers.^{4,38-42}

In the future, treatment of complicated chronic wounds may be similar to the treatment of other complicated diseases, including rejection of a transplanted organ, tumor metastasis, and acquired immunodeficiency syndrome, for which multiple combinations of medications are necessary. The data presented herein demonstrate that Apligraf should be part of the armamentarium used in treating these complicated wounds.

Recognition that a chronic wound by definition has a physiologic impairment to healing is important in designing a treatment plan. Initial recognition of a diabetic ulcer should prompt an immediate visit with the patient's physician, podiatrist, and surgeon. The possibility for vascular intervention should be assessed simultaneously. Both diabetic and pressure ulcers originate at the skin level. The data presented in this study document that when infection is controlled by debridement and other appropriate therapy, biological intervention provides a choice that assures lack of progression in both diabetic and pressure ulcers. This concept of early intervention to prevent amputation is well documented in the literature.⁵¹⁻⁵⁴ All patients with diabetes and who are at risk for pressure wounds (ie, those with spinal cord injuries and bedridden patients) should be examined daily. Any new wound in these patients requires mandatory intervention. In this article, we describe one treatment regimen that should be used in the future to accelerate the healing of diabetic and pressure ulcers and to ensure lack of progression of these wounds.

Presented at the 107th Scientific Session of the Western Surgical Association, Santa Fe, NM, November 16, 1999.

This study was supported in part by a research grant from the Eastern Paralyzed Veterans Association, Jackson Heights, NY (Dr Brem).

The authors thank Tom Jacobs, Gae O. Decker-Garrad, and Pamela Talalay for editorial assistance.

Corresponding author: Harold Brem, MD, The Mount Sinai Medical Center, 5 E 98th St, Box 1259, New York, NY 10029-6574 (e-mail: haroldbrem@earthlink.net).

REFERENCES

1. Allman RM. Pressure ulcer prevalence, incidence, risk factors, and impact. *Clin Geriatr Med*. 1997;13:421-436.
2. Nelzen O, Bergqvist D, Lindhagen A, et al. Chronic leg ulcers: an underestimated problem in primary health care among elderly patients. *J Epidemiol Community Health*. 1991;5:184-191.
3. Harris MI, Cowie CC, Reiber G, Boyko E, Stern M, Bennett P, eds. *Diabetes in America*. Washington, DC: US Government Printing Office; 1995.
4. Centers for Disease Control and Prevention. *National Diabetes Fact Sheet: National Estimates and General Information on Diabetes in the United States*. Rev ed. Atlanta, Ga: US Dept of Health and Human Services, Centers for Disease Control and Prevention; 1998.
5. Pecoraro RE, Reiber GE, Burgess EM. Pathways to diabetic limb amputation. *Diabetes Care*. 1990;13:513-521.
6. Reiber GE, Boyko EJ, Smith DG. Lower extremity foot ulcers and amputations in diabetes. In: Harris MI, Cowie CC, Reiber G, Boyko E, Stern M, Bennett P, eds. *Diabetes in America*. Washington, DC: US Government Printing Office; 1995: 409-428.
7. Eckman MH, Greenfield S, Mackey WC, et al. Foot infections in diabetic patients: decision and cost-effectiveness analyses. *JAMA*. 1995;273:712-720.
8. O'Brien SP, Gahtan V, Wind S, Kerstein MD. What is the paradigm: hospital or home health care for pressure ulcers? *Am Surg*. 1999;65:303-306.
9. Allman R. Pressure ulcer prevalence, incidence, risk factors, and impact. In: Thomas DR, Allman RM, eds. *Clinics in Geriatric Medicine*. Philadelphia, Pa: WB Saunders Co; 1997:421-436.
10. Moody BL, Fanale JE, Thompson M, Vaillancourt D, Symonds G, Bonasoro C. Impact of staff education on pressure ulcer sore development in elderly hospitalized patients. *Arch Intern Med*. 1988;148:2241-2243.
11. Scheckler WE, Peterson PJ. Infections and infection control among residents of eight rural Wisconsin nursing homes. *Arch Intern Med*. 1986;146:1981-1984.
12. Shannon ML, Skorga P. Pressure ulcer prevalence in two general hospitals. *Decubitus*. 1989;2:38-43.
13. Pase MN. Pressure relief devices, risk factors, and development of pressure ulcers in elderly patients with limited mobility. *Adv Wound Care*. 1994;7:38-42.
14. Brandeis GH, Morris JN, Nash DJ, Lipsitz LA. The epidemiology and natural history of pressure ulcers in elderly nursing home residents. *JAMA*. 1990;264: 2905-2909.
15. Allman RM. Pressure ulcers among the elderly. *N Engl J Med*. 1989;320:850-853.
16. Allman RM. Outcomes in prospective studies and clinical trials. *Adv Wound Care*. 1995;8(suppl):61-64.
17. Nathan CF. Secretory products of macrophages. *J Clin Invest*. 1987;79:319-326.
18. Brem H, Folkman J. Angiogenesis and basic fibroblast growth factor during wound healing. In: Brighton CT, Friedlander GE, Lane JM, eds. *Bone Formation and Repair*. Rosemont, Ill: American Academy of Orthopedic Surgeons; 1994:213-222.
19. Lazarus GS, Cooper DM, Knighton DR, et al. Definitions and guidelines for assessment of wounds and evaluation of healing. *Arch Dermatol*. 1994;130:489-493.
20. Mostow EN. Diagnosis and classification of chronic wounds. *Clin Dermatol*. 1994; 12:3-9.
21. Steed DL. Foundations of good care. *Am Surg*. 1998;176(suppl 2A):20S-25S.
22. Knight EV, Oldham JW, Mohler MA, Liu S, Dooley J. A review of nonclinical toxicology studies of becaplermin (rhPDGF-BB). *Am Surg*. 1998;176(suppl 2A):55S-60S.
23. LeGrand EK. Preclinical promise of becaplermin (rhPDGF-BB) in wound healing. *Am Surg*. 1998;176(suppl 2A):26S-38S.
24. Muhart M, McFalls S, Kirsner RS, et al. Behavior of tissue-engineered skin: a comparison of a living skin equivalent, autograft, and occlusive dressing in human donor sites. *Arch Dermatol*. 1999;135:913-918.
25. Eaglstein WH, Iriondo M, Laszlo K. A composite skin substitute (Graftskin) for surgical wounds: a clinical experience. *Dermatol Surg*. 1995;21:839-843.
26. Falabella AF, Schachner LA, Valencia IC, Eaglstein WH. The use of tissue-engineered skin (Apligraf) to treat a newborn with epidermolysis bullosa. *Arch Dermatol*. 1999;135:1219-1222.
27. Sabolinski ML, Alvarez O, Auletta M, Mulder G, Parenteau NL. Cultured skin as a "smart material" for healing wounds: experience in venous ulcers. *Biomaterials*. 1996;17:311-320.
28. Falanga V. How to use Apligraf to treat venous ulcers. *Skin Ageing*. 1999;25:30-36.
29. Falanga V, Margolis D, Alvarez O, et al. Rapid healing of venous ulcers and lack of clinical rejection with allogeneic cultured human skin equivalent. *Arch Dermatol*. 1998;134:293-300.
30. Parenteau N. Skin: the first tissue-engineered products. *Sci Am*. 1999;280:83-84.
31. Fiala TG, Andrew Lee WP, Hong HZ, May JW Jr. Bacterial clearance capability of living skin equivalent, saline dressing, and xenograft dressing in the rabbit. *Ann Plast Surg*. 1993;30:516-519.
32. Falanga V, Sabolinski M. A bilayered skin construct (Apligraf) accelerates complete closure of hard-to-heal venous ulcers. *Wound Repair Generation*. 1999;7: 201-207.
33. Parenteau NL, Nolte CM, Bilbo P, et al. Epidermis generated in vitro: practical considerations and applications. *J Cell Biochem*. 1991;45:245-251.
34. Bell E, Rosenberge M, Kemp P, et al. Recipes for reconstituting skin. *J Biomech Eng*. 1991;113:113-119.
35. Zieskeh JD, Mason VS, Wasson ME, et al. Basement membrane assembly and differentiation of cultured corneal cells: importance of culture environment and endothelial cell interaction. *Exp Cell Res*. 1994;214:621-633.
36. Maklebust J. Pressure ulcer assessment. In: Thomas DR, Allman RM, eds. *Clinics in Geriatric Medicine: Pressure Ulcers*. Philadelphia, Pa: WB Saunders Co; 1997:455-473.
37. Pruitt BA Jr, McManus AT, Kim SH, Goodwin CW. Burn wound infections: current status. *World J Surg*. 1998;22:133-145.
38. Steed DL, Donohue D, Webster MW, et al. Effect of extensive debridement and treatment on the healing of diabetic foot ulcers. *J Am Coll Surg*. 1996;183:61-64.
39. Proceedings of the 5th Annual Meeting of the European Tissue Repair Society, Padova, Italy, August 30-September 2, 1995 [abstract]. *Wound Repair Regen*. 1995;3:359.
40. Pham HT, Rosenblum BI, Lyons TE, et al. Evaluation of a human skin equivalent for the treatment of diabetic foot ulcers in a prospective randomized, clinical trial. *Wounds*. 1999;11:79-86.
41. Levenson SM, Demetriou AA. Metabolic factors. In: Cohen IK, Diegelmann RF, Lindblad WJ, eds. *Wound Healing Biochemical and Clinical Aspects*. Philadelphia, Pa: WB Saunders Co; 1992:248-273.
42. Pecoraro RE, Reiber GE, Burgess EM. Pathways to diabetic limb amputation: basis for prevention. *Diabetes Care*. 1990;13:513-521.
43. Smiell JN, and the Becaplermin Study Group. Clinical safety of becaplermin (rhPDGF-BB) gel. *Am J Surg*. 1998;176(suppl 2A):68S-73S.
44. El Saghir NS, Bizri AR, Shabb NS, Husami TW, Salem Z, Shamseddine AI. Pressure ulcer accelerated healing with local injections of granulocyte macrophage-colony stimulating factor. *J Infect*. 1997;35:179-182.
45. Arnold F, O'Brien J, Cherry G. Granulocyte monocyte-colony stimulating factor as an agent for wound healing: a study evaluating the use of local injections of a genetically engineered growth factor in the management of wounds with a poor healing prognosis. *J Wound Care*. 1995;4:400-402.
46. Marques da Costa R, Jesus MF, Aniceto C, Mendes M. Double-blind randomized placebo-controlled trial of the use of granulocyte-macrophage colony-stimulating factor in chronic leg ulcers. *Am J Med*. 1997;173:165-168.
47. Wheeler G, Brodle GN. GM-CSF and wound healing [letter]. *Med J Aust*. 1998; 168:580.
48. Jaschke E, Zabernigg A, Gattringer C. Recombinant human granulocyte-macrophage colony-stimulating factor applied locally in low doses enhances healing and prevents recurrence of chronic venous ulcers. *Int J Dermatol*. 1999;38: 380-386.
49. Remes K, Ronnemaa T. Healing of chronic leg ulcers in diabetic necrobiosis lipoidica with local granulocyte-macrophage colony stimulating factor treatment. *J Diabetes Complications*. 1999;13:115-118.
50. Jung RW, Wu L, Pierce GF. Granulocyte-macrophage colony-stimulating factor and granulocyte colony-stimulating factor: differential action on incisional wound healing. *Surgery*. 1994;115:325-334.
51. Akbari CM, LoGerfo FW. Diabetes and peripheral vascular disease. *J Vasc Surg*. 1999;24:373-384.

52. LoGerfo FW, Coffman JD. Vascular disease of the lower extremities in diabetes mellitus. *Endocr Metab Clin North Am*. 1996;30:499-508.
53. Berceli SA, Chan AK, Pomposeli FB, et al. Efficacy of dorsal pedal artery bypass in limb salvage for ischemic heel ulcers. *J Vasc Surg*. 1999;30:499-508.
54. LoGerfo FW, Coffman JD. Vascular and microvascular disease of the foot in diabetes. *N Engl J Med*. 1984;311:1615-1619.

DISCUSSION

Cleon W. Goodwin, Jr, MD, Fort Sam Houston, Tex: The history of chronic wound management is passionate and contradictory and is usually based on case series. When I was an eager and naïve surgical resident, I was interested in these types of wounds. I learned very quickly what all of my predecessors all knew to be true—that the interest itself and the related increase in wound care often resulted in improved wound healing unrelated to the magic agent being investigated. This has been called by some the Hawthorne effect. Clinical trials with appropriate controls, including the adjuvant therapy that Dr Brem talked about, are essential to evaluate the new high tech, very expensive solutions now being offered by the biotechnology industry.

Why Apligraf? Over a decade ago Hefton and Stiano-Coico down the street from Dr Brem at Cornell demonstrated that allogeneic donor keratinocytes do not persist and are replaced by host keratinocytes and that the donor keratinocytes act primarily as delivery vehicles for various growth hormones. So what's new about Apligraf and your technique?

The second question: You state in your paper that Apligraf is distinct and more effective in healing these recalcitrant wounds than autologous skin graft. This is certainly contrary to conventional thinking. What are your data for this statement?

Finally, you state that the closeable wound bed must be free of infection. Do you confirm this with quantitative wound biopsy, as advised by Robson and many others?

J. David Richardson, MD, Louisville, Ky: Dr Brem, my question is a cost question, especially if you are trying to convince someone that it is more than a Hawthorne effect and you are trying to look at the cost of the treatment itself. Have you done any cost analysis? What does the Apligraf itself cost, and how does that work?

Fabrizio Michelassi, MD, Chicago, Ill: In Crohn's disease, pyoderma gangrenosum can create difficult ulcers to heal. Although we all understand that the primary therapy should be directed to the active Crohn's disease, those ulcers may be difficult to heal. Have you used human skin equivalent in pyoderma gangrenosum at your institution where you obviously see a lot of patients with inflammatory bowel disease?

Dr Hollier: Of all topics in surgery, one of the most challenging to solve is chronic wounds. It is also the ones that sur-

geons in general least like to take care of. Surgeons by their very personality like quick answers, quick solutions. Anything that doesn't heal right away, we are not exactly interested in that. The comments by Dr Goodwin are very pertinent in that interest clearly does make a difference, particularly the difficult-to-heal wound. There is nothing like persistence, daily care, daily inspection, and persistence that will allow the best opportunity for healing.

The question, were clinical trials performed? Clinical trials have already been performed looking at Apligraf vs best conventional therapy for venous disease and diabetic ulcers. There has not been a clinical trial for pressure ulcers. That is clearly the next step. Our work started initially with an interest in the chronic venous ulcer, those that had been there for greater than a year, where only 19% healed with best medical therapy. Even with an aggressive surgical approach of interruption of deep perforators, it is rare to get greater than 50% healing and that usually does not persist. So there is room for further clinical trials.

Why Apligraf? If one takes the conventional skin graft, one may have growth factors that are produced, but it is a relatively stable state. The keratinocytes and fibroblasts that are made for Apligraf are taken from all places the foreskin of neonates. These cells are actively dividing, actively producing growth factors. These sheets of Apligraf have to be applied within five days of receiving them, so there is a time element, but these are growth factories of making growth factors. If one could take an analogy with the tobacco industry when one might say that a cigarette is a delivery mechanism for the drug nicotine, one might say that the Apligraf is a delivery vehicle for 15 growth factors. There is some excellent work done previously by Dr Jan Young by polymerase chain reaction analysis showing that there are 15 different growth factors that are synthesized by the keratinocytes and fibroblasts of this product. It is opening up a new realm for surgeons, not only here in the management of wounds, but also in the future era of gene therapy.

Dr Richardson asked about the cost. The cost is roughly \$975 a sheet. Fortunately only one application is all that has been required in most of our patients. Otherwise the hospital would probably have run us out. But we have been able to demonstrate however that just a single day short of hospital stay saves that money. Our cost is about \$1000 a day. Furthermore, if you are taking a patient with a pressure ulcer in an intensive care unit setting, unfortunately there are some patients who have bills of over \$200,000 run up because of inability to heal pressure ulcers. So clearly we need further studies to see whether or not the cost effectiveness will really be shown through.

Dr Michelassi had excellent questions about Crohn's disease. Mount Sinai is rife with Crohn's disease patients. We have not yet studied the wound complications of Crohn's disease, but it is crying for a study going forward.

Quotation

It is the surgeon's duty to tranquilize the temper, to beget cheerfulness, and to impart confidence of recovery.

Sir Astley Paston Cooper
1768-1841

Reference: *Lectures on Surgery*. Lecture I.